



CORTICOIDS IN ANALGESIA FOR POSTOPERATIVE PAIN CONTROL IN RESECTION OF DIGITAL FIBROKERATOMA A Case Report

ÁNGEL O. JAIMES¹, PAULA A. GUTIERREZ-MARIN², LIGIA MÉNDEZ-GAVIRIA³, JAVIER HERNANDEZ-MORENO⁴

¹ Oncologist Dermatology, Hospital Militar Central, Colombia

² Dermatology Resident. Nueva Granada Military University - Hospital Militar Central, Colombia

³ General Dermatology, Hospital Militar Central, Colombia

⁴ Dermatopathology, Hospital Militar Central, Colombia

KEYWORDS

Anesthesia
Analgesia
Glucocorticoid
Triamcinolone
Fingers
Nails
Fibroma

ABSTRACT

Postoperative pain control in surgeries performed on the nail apparatus is a challenge in dermatological practice. The use of corticosteroids (from now on, CE) in combination with intradermal or intralesional anesthetics has been used by other specialties to control joint pain and postoperative analgesia. Could this practice reduce pain in patients where the nail apparatus is manipulated? We present the case of a 50-year-old patient with onychodynia in whom the presence of a digital fibrokeratoma was diagnosed. For the surgical resection of this tumor, perioperative analgesia with triamcinolone acetonide (from now on, TA) was used, achieving adequate control of postoperative pain.

Received: 25/ 01 / 2023

Accepted: 07/ 03 / 2023

1. Introduction

Postoperative pain control in surgeries performed on the nail apparatus is a challenge in dermatological practice.

The use of CE in combination with intradermal or intralesional anesthetics has been used by other specialties to control joint pain and manage postoperative analgesia. Could this practice reduce pain in patients where the nail apparatus is manipulated? (Di Chiacchio et al., 2019).

2. Case presentation

A 50-year-old female patient with a 2-year history of onychodynia in the left thumb, associated with a cut in the nail plate. Subsequently, she recognized a subungual mass in the middle third of the hyponychium, which is why she consulted (Fig.1. A, B, C). It was decided to perform a partial exeresis of the nail plate (Fig. 2). Perioperative analgesia is used with 2.5mg (0.5ml) of TA + 2.5mg (0.5ml) of bupivacaine with epinephrine, subsequently excision of the nail plate is performed with the nail bed and subcutaneous tissue. During the postoperative (POP), acetaminophen is used as an alternative, other analgesics are not used. The histopathological study report concludes that it is a digital fibrokeratoma (Fig 4. A, B). The patient reports a VAS (Visual Analogue Scale) on day 1 of the POP with a value of 0, one week after the POP, a value of 0, and one month after the POP, a value of 0. She had adequate pain control in the POP. One month after surgery, there were no adverse or secondary effects to the use of the corticosteroid (Fig 3.).

Figura 1. Digital fibrokeratoma.

Figura 2. Partial excision of nail plate.

Figura 3. Postoperative of partial excision of nail plate.

Figura 4. Histopathological study, Hematoxilyn and eosin.

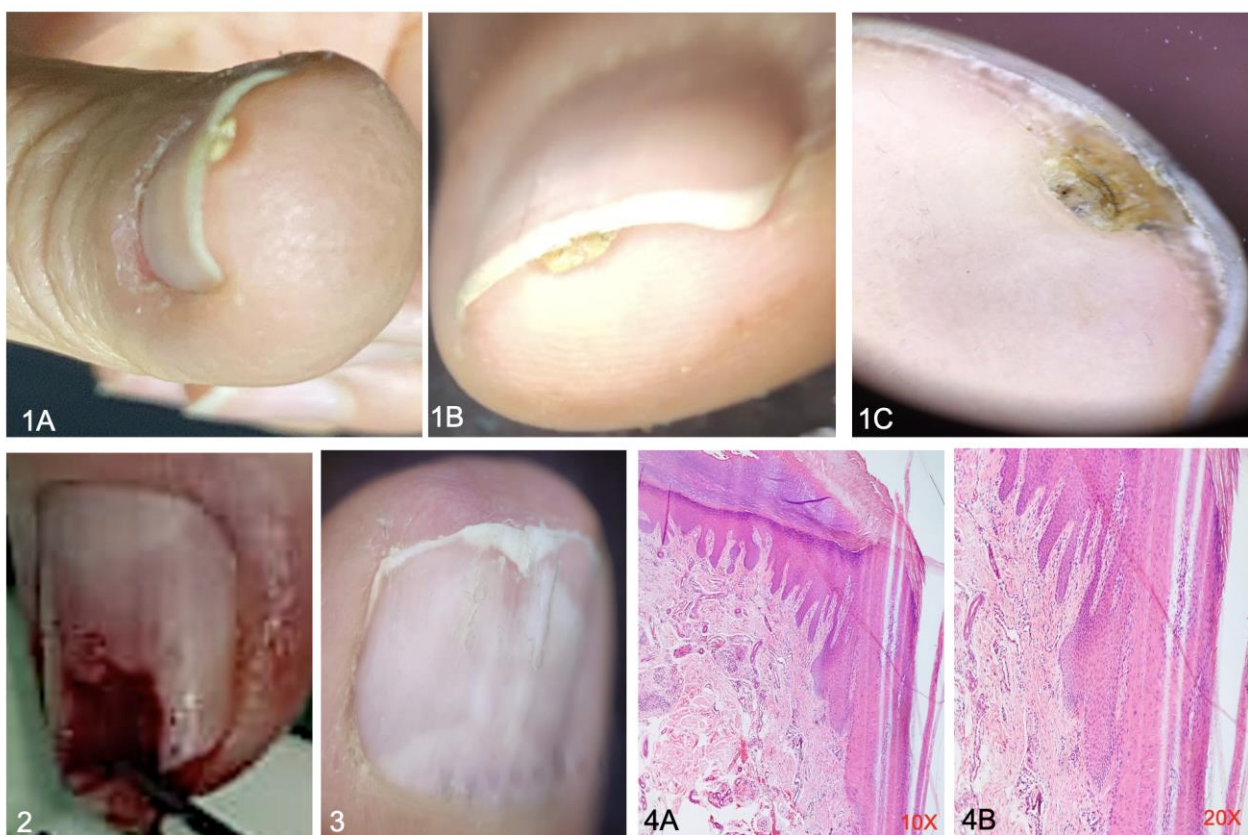


Fig 1. A, B, C. Subungual digital fibrokeratoma in hyponychium. 2. Partial excision of nail plate. 3. Postoperative period of partial excision of the nail plate. distal 4. A and B. Hematoxylin and eosin (H&E) Hyperkeratotic epidermis with foci of parakeratosis. Dermis with increased stellate fibroblasts on fibrous stroma associated with dilated blood vessels. All photos were taken from patient as well as H&E at Hospital Militar Central, Bogotá, Colombia.

Fuente(s): Jaimes-Angel Omar and Javier Hernandez-Moreno, pictures from patient, 2023.

3. Discussion

Digital fibrokeratoma is a generally solitary benign tumor, euchromic, with dome-shaped or elongated horn-shaped morphology, which can appear secondary to trauma (Yélamos et al., 2013).

This term covers different entities such as acral fibrokeratoma, acquired periungual fibrokeratoma, “garlic tooth” fibroma, and subungual and periungual fibromas, characteristic of tuberous sclerosis (Hurt & Weedon, 2012). The removal of these tumors is performed when they produce symptoms or when there is a significant aesthetic alteration. Pain management at the time of resection of this type of tumor, which can be considerable size, is frequently a challenge in dermatological surgery (Yélamos et al., 2013).

Intralesional corticosteroids together with injectable anesthetics are used for joint pain control (Kloppenborg & Berenbaum, 2020), plantar pain management, adjuvants for peripheral neural blockade (Pehora et al., 2017), with adequate response, reduction of subjective pain scales and prolongation of anesthetic action (Jegal et al., 2019). As an infrequent adverse effect, it has been seen that the use of intra-articular steroids for more than 2 years leads to the loss of bone cartilage, which has been evidenced in radiological studies (Jegal et al., 2019). The incidence of secondary or adverse effects on the skin and adnexa due to the use of perioperative CE in procedures involving the nail apparatus has not been described (Shailee & Tosti, 2014).

For this reason, we wonder if it can be an alternative for pain management in surgery of the nail apparatus.

In the literature review, we found a randomized controlled study where 16 patients were included to evaluate postoperative pain control with the use of intralesional corticosteroids versus not using them. Anesthetic solution with TA was injected into 50% of the patients, and anesthetic without TA was injected into the other 50%. As a result, better control of POP pain was observed in patients who had analgesia with TA. We did not find other reports of the use of this combination for pain management, however it is the same result that we obtained in our patient, considerable improvement in the subjective pain scale (Di Chiacchio et al., 2019; Kloppenburg & Berenbaum, 2020).

We believe that more studies should be carried out to identify if there are side effects from the use of corticosteroids in perioperative analgesia in the nail apparatus, or if, on the contrary, it is a technique that helps us not only to control pain, but also to avoid complications and speed up the recovery process in the postoperative period (Di Chiacchio et al., 2019).

In our experience, we consider that perioperative analgesia with corticosteroids is safe: this is put into practice in our training center, and we recommend it for postoperative pain management in surgeries involving the nail apparatus.

4. Conclusion

- The use of corticosteroids for perioperative analgesia is a new strategy for postoperative pain control and accelerates recovery.
- Currently, no side effects have been identified, however, the study of a larger number of patients is important (Shailee & Tosti, 2014).
- For perioperative anesthesia in nail apparatus, TA + bupivacaine or lidocaine with epinephrine could be used in equal amounts for example (1 mL of the solution containing 0.5 mL of lidocaine or bupivacaine and 0.5 mL of triamcinolone [10 mg/mL]). This will also control postoperative pain (Di Chiacchio et al., 2019).

5. Patient's perspective

She did not feel pain at any time during the postoperative period. Refers to feeling satisfied after the partial exeresis of the nail plate since she does not present onychodinia.

6. Learning points

Anesthetic plus corticosteroid allow satisfactory analgesia perioperatory and postoperative pain control.

TA + bupivacaine or lidocaine with epinephrine could be used in equal amounts for example (1 mL of the solution containing 0.5 mL of lidocaine or bupivacaine and 0.5 mL of triamcinolone [10 mg/mL])

More study should be carried out to determine the side effects of CE surgeries of the nail apparatus.

References

- Di Chiacchio, N., Ocampo-Garza, J., Villarreal-Villarreal, C. D., Ancer-Arellano, J., Noriega, L. F., & Di Chiacchio, N. G. (2019). Post-nail procedure analgesia: A randomized control pilot study. In *Journal of the American Academy of Dermatology*, 81(3), 860–862. <https://doi.org/10.1016/j.jaad.2019.05.015>
- Hurt, M. A., & Weedon, D. (2012). Weedon D. Weedon's Skin Pathology. 3rd ed. London: Churchill Livingstone Elsevier, 2010. In *Dermatology Practical & Conceptual*, 2(1), 79–82. <https://doi.org/10.5826/dpc.0201a15>
- Jegal, M., Woo, S. J., Il Lee, H., Shim, J. W., & Park, M. J. (2019). Effects of simultaneous steroid injection after percutaneous trigger finger release: a randomized controlled trial. *The Journal of Hand Surgery, European Volume*, 44(4), 372–378. <https://doi.org/10.1177/1753193418813771>
- Kloppenborg, M., & Berenbaum, F. (2020). Osteoarthritis year in review 2019: epidemiology and therapy. *Osteoarthritis and Cartilage*, 28(3), 242–248. <https://doi.org/10.1016/j.joca.2020.01.002>
- Yélamos, O., Alegre, M., Garcés, J.R., L. Puig. (2013). Periungual Acral Fibrokeratoma: Surgical Excision Using a Banner Flap. *Actas Dermo-Sifiliográficas*, 104(9), 830–832.
- Pehora, C., Pearson, A. M., Kaushal, A., Crawford, M. W., & Johnston, B. (2017). Dexamethasone as an adjuvant to peripheral nerve block. *The Cochrane Database of Systematic Reviews*, 11(11), CD011770. <https://doi.org/10.1002/14651858.CD011770.pub2>
- Shailee, P., & Tosti, A. (2014). An overview of management of drug induced hair and nail disorders. *Future Medicine Ltd*, 11(3), 327–338.